

# Pericardial Disease



Images from an MRI can help your doctor understand if there are issues with your heart

## SYMPTOMS AND DESCRIPTION

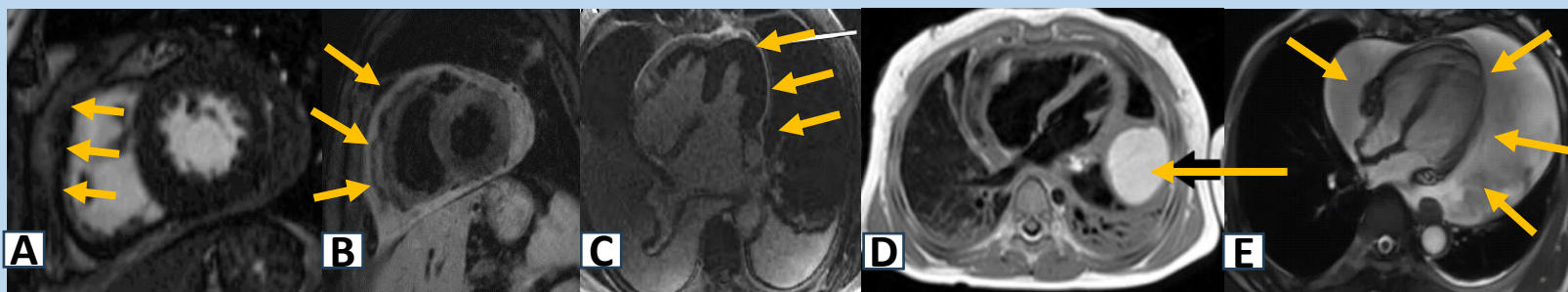
Symptoms include: Chest pain, difficult catching a breath, dizziness, fainting spells, and leg swelling.

Description: This is a disease affecting the outer layer of the heart and can include abnormal masses, inflammation and collection of fluid, and increased thickness. It can be caused by infections, inflammation, spread of cancer, drugs, radiation therapy, and trauma.

## WHY MRI

Heart MRI captures clear images of your heart and can find any abnormal structures. It can also give your doctor information about what it is made of and whether it is cancerous. Depending on how the other chambers and structures are affected, your doctor may need to refer you for surgery or procedure.

## IMAGES



Different types of pericardial diseases are shown (highlighted by orange arrows). A and B: Thickened pericardium. C: Inflammation of the pericardium (arrow) which resolved after treatment. D: Pericardial cyst (arrow). E: Large pericardial effusion which required urgent drainage.

Ask your doctor about:

Cardiac MRI with contrast

*Images provided courtesy of: (A-B) Ming-Yen Ng, MBBS, Mirza Ahmad, MD; (C) Fawad Khaliq, MD, Haroon Yousaf, MD, Daniel Bloomgarden, MD, PhD, and Khawaja Afzal Ammar, MD; (D) Frank J. Raucci Jr. MD PhD, Patrick R. Holmes MD, Brett A. Mettler MD, and Jason T. Christensen MD; (E) Hui Chen, MD, Xiaohai Ma, MD, PhD, Lei Zhao, MD, PhD, Zheng Wang, PhD, Feng Gao, MD, Zhanming Fan, Jianfeng Shang, and Chiara Bucciarelli-Ducci, MD, PhD. Created by: Ming-Yen Ng, MBBS and Kanae Mukai, MD.*